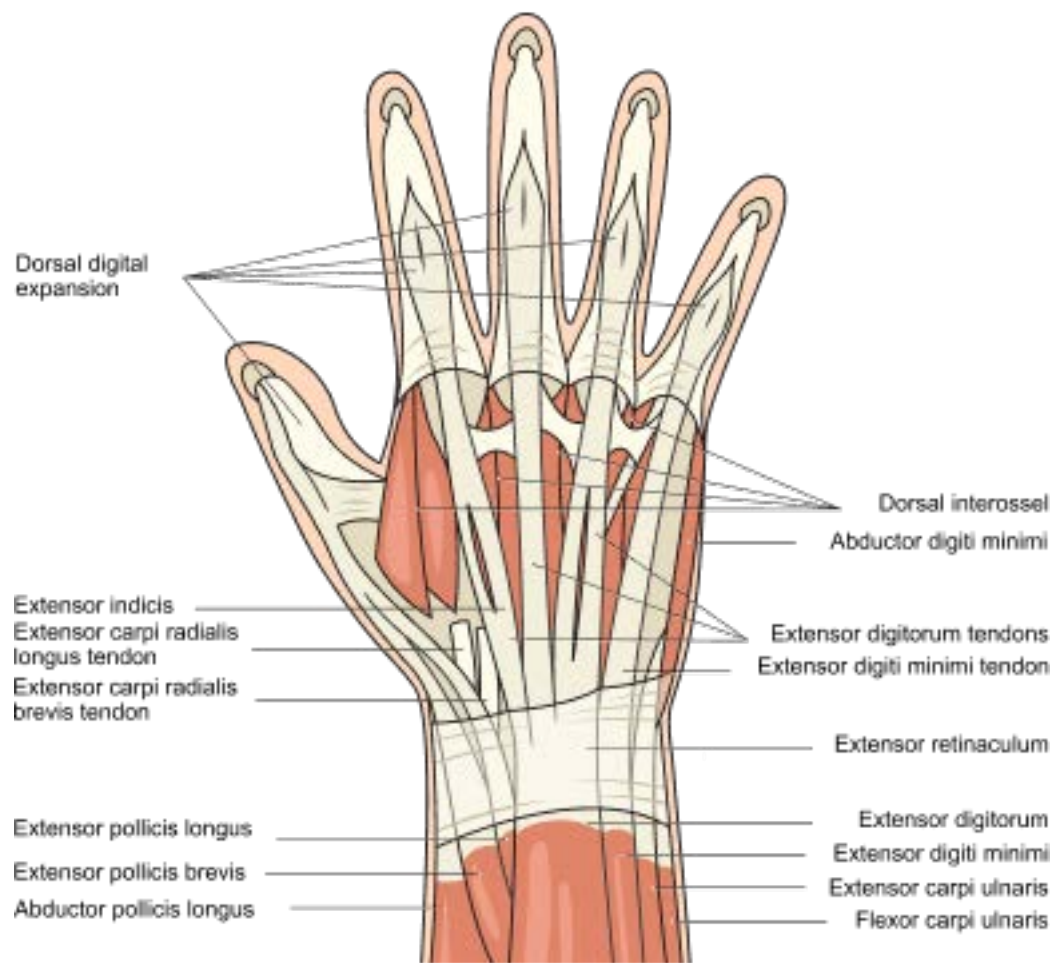
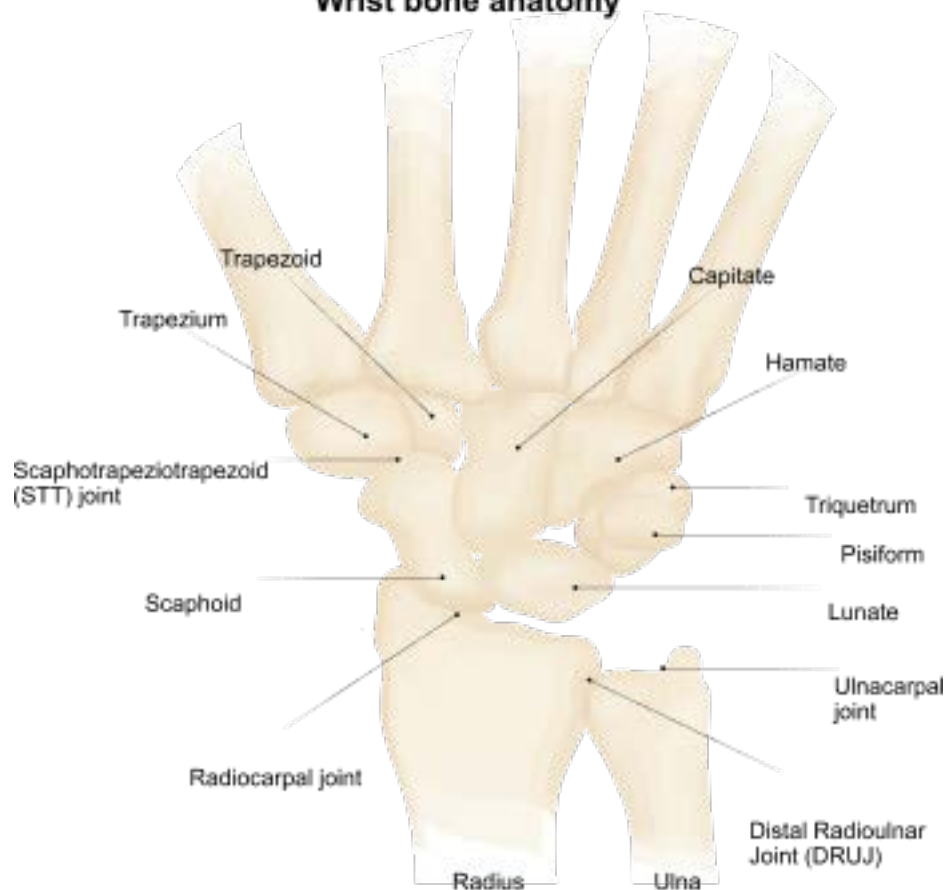


Wrist Anatomy

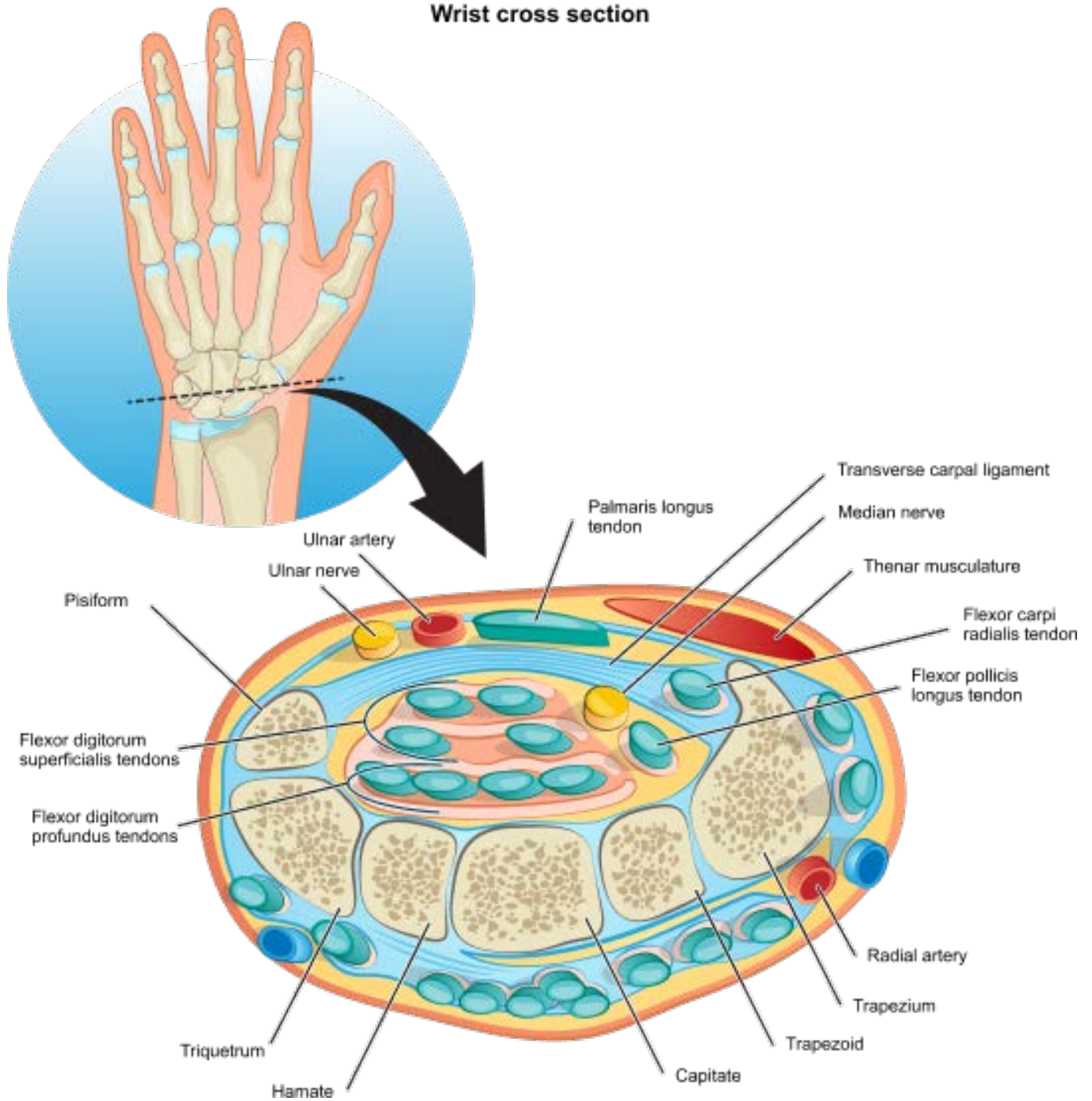
Anatomy of the hand and wrist



Wrist bone anatomy



Wrist cross section



Key components

Wrist bones

- **Proximal carpal row (scaphoid, lunate, triquetrum, pisiform):** The proximal carpal row consists of four bones, namely the scaphoid, lunate, triquetrum, and pisiform. These bones are located on the proximal side (closer to the forearm) of the wrist joint. They play a crucial role in wrist mobility and stability.
- **Distal carpal row (trapezium, trapezoid, capitate, hamate):** The distal carpal row contains four bones, namely the trapezium, trapezoid, capitate, and hamate. These bones are located on the distal side (closer to the hand) of the wrist joint. They work together with the proximal carpal row to provide stability and support to the wrist joint during movement.

Muscle and tendons

- **Flexor tendons (flexor carpi radialis, flexor carpi ulnaris tendon):** The flexor tendons are located on the anterior (front) side of the wrist and are responsible for bending the wrist joint. The flexor carpi radialis tendon is located closer to the thumb side, while the flexor carpi ulnaris tendon is situated closer to the pinky finger.
- **Extensor tendons (extensor carpi radialis brevis tendon, extensor carpi radialis longus tendon, extensor carpi ulnaris tendon):** The extensor tendons are located on the posterior (back) side of the wrist and are responsible for straightening the wrist joint. They also play a role in stabilizing the wrist during gripping activities.
- **Nerves (median, radial, ulnar):** The wrist joint is innervated by three main nerves - the median nerve, radial nerve, and ulnar nerve. These nerves provide sensory and motor functions to the hand and fingers. They also play a role in wrist movement and coordination.

Ligaments (Radial collateral, dorsal radiocarpal, ulnar collateral, volar carpal)

Ligaments are tough, fibrous tissues that connect bones to other bones and help provide stability and support to the joint. In the wrist, there are four main ligaments - the radial collateral ligament, dorsal radiocarpal ligament, ulnar collateral ligament, and volar carpal ligament.

Blood and lymphatic vessels

In addition to nerves, muscles, and tendons, the wrist also contains a network of blood and lymphatic vessels. These vessels supply nutrients and oxygen to the wrist joint and surrounding tissue, while also helping to remove waste products.

Additional notes