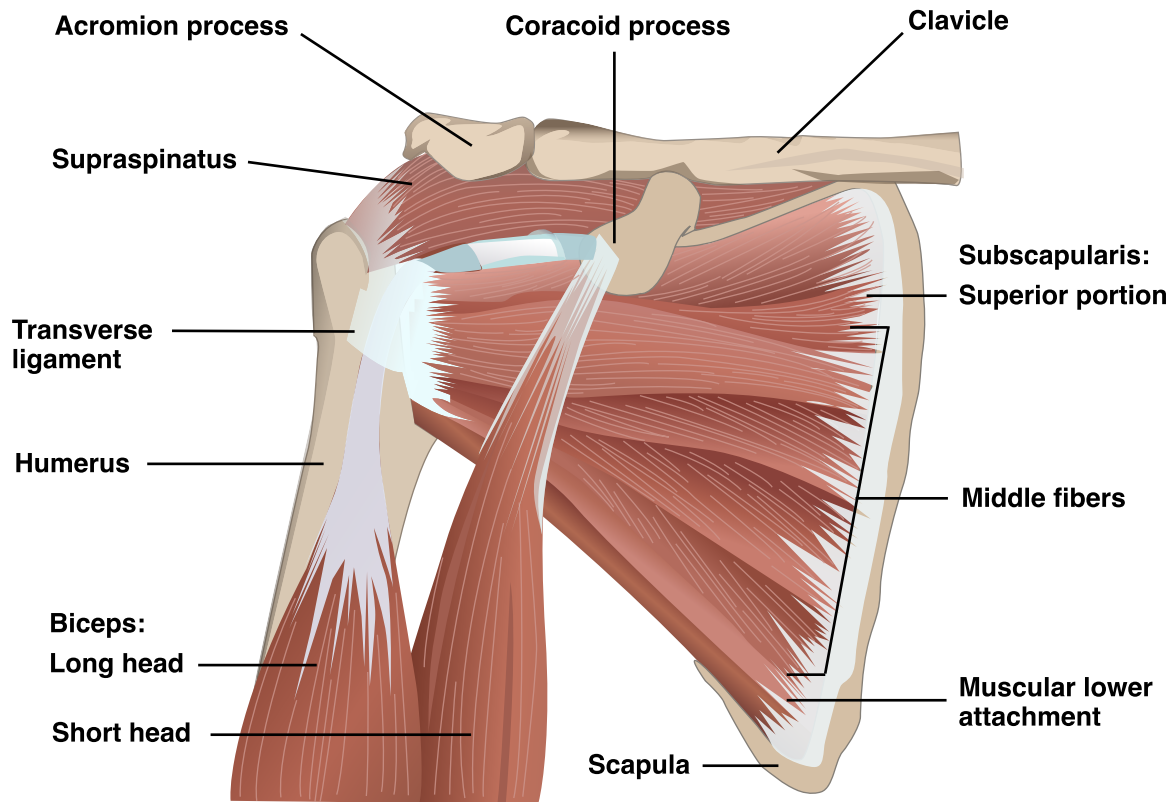


Subscapularis Anatomy Diagram



The diagram illustrates the anatomy of the shoulder, specifically focusing on the subscapularis muscle and its surrounding structures. Key elements labeled in the diagram include:

- **Acromion process:** A bony projection of the scapula, part of the shoulder blade.
- **Coracoid process:** A small hook-like structure on the scapula.
- **Clavicle:** Also known as the collarbone, connecting the shoulder blade to the sternum.
- **Supraspinatus:** One of the rotator cuff muscles located above the subscapularis.
- **Transverse ligament:** Connects the bony points on the humerus and scapula, stabilizing the biceps tendon.
- **Humerus:** The upper arm bone.
- **Biceps (long head and short head):** The muscle with two tendons (long and short head) that attach to the shoulder.
- **Subscapularis (superior portion, middle fibers, muscular lower attachment):** The primary muscle illustrated, showing its different portions and attachments on the scapula.
- **Scapula:** The shoulder blade.

Notes

Mallac, C. (n.d.). As the shoulder turns: Understanding the subscapularis - Part I. *Sports Injury Bulletin*. <https://www.sportsinjurybulletin.com/diagnose--treat/as-the-shoulder-turns-understanding-the-subscapularis-part-i>