Royal London Hospital Test

Patient information	
Name: George Worth	**Age:** 24
Gender: Male	**Date:** July 30, 2025
Examiner name: Dr. Aldrin Cane	

Test procedure

1. Position the patient in a seated posture with the foot hanging off the edge of the bench.
2. Ensure the ankle is in a neutral or slightly plantarflexed position.
3. Palpate the Achilles tendon to identify a tender spot. In midportion Achilles tendinopathy, this is typically 2–5 cm above the calcaneal insertion. In insertional tendinopathy, tenderness is usually located directly at the calcaneus.
4. Ask the patient to actively dorsiflex the ankle to its maximum range.
5. While the ankle is dorsiflexed, palpate the previously identified tender spot again.
6. Next, ask the patient to actively plantarflex the ankle to its maximum range.
7. Palpate the same spot once more to reassess for tenderness.

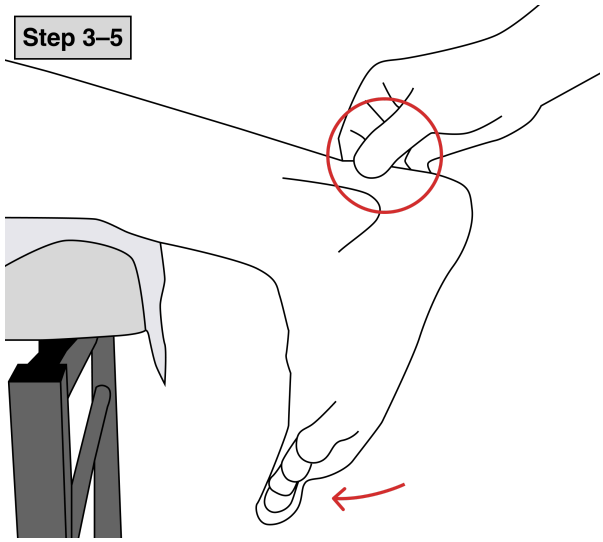

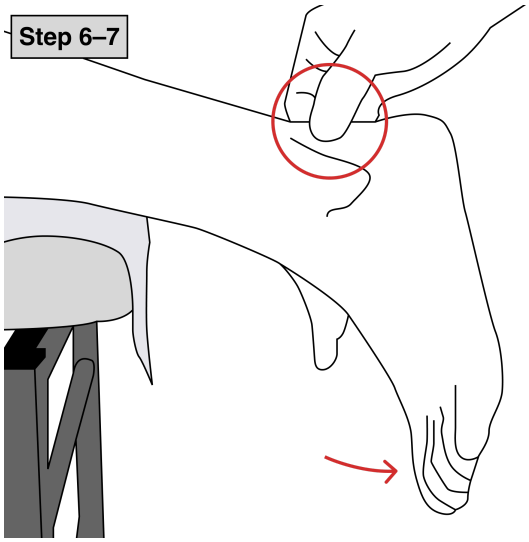

Findings

- (●) Positive – The previously tender area is no longer painful during maximum dorsiflexion.
- ( ) Negative – The tenderness remains present during maximum dorsiflexion.

Additional notes
Requested an X-ray for more accurate diagnosis. Recommended RICE and ibuprofen for the time being.

Reiman, M. et al. (2014). The utility of clinical measures for the diagnosis of Achilles tendon injuries: A systematic review with meta-analysis. *Journal of Athletic Training*, 49(6), 820–829.

Maffulli, N. et al. (2003). Clinical diagnosis of Achilles tendinopathy with tendinosis. *Clinical Journal of Sport Medicine*, 13(1), 11–15.

Manzanares, A. (2021). *Effectiveness of a load management program complemented with tendon neuroplastic training (TNT) for the treatment of chronic non-insertional Achilles tendinopathy: A research protocol [Research]*. In ResearchGate. https://www.researchgate.net/publication/349916175_EFECTIVIDAD_DE_UN_PROGRAMA_DE_GESTION_DE_LA_CARGA_COMPLEMENTADO_CON_ENTRENAMIENTO_NEUROPLASTICO_DEL_TENDON_TNT_PARA_EL_TRATAMIENTO_DE_LA_TENDINOPATIA_AQUILEA_NO_INSERCIONAL_CRONICA_PROTOCOLO_DE_INVEST