

Penetration-Aspiration Scale

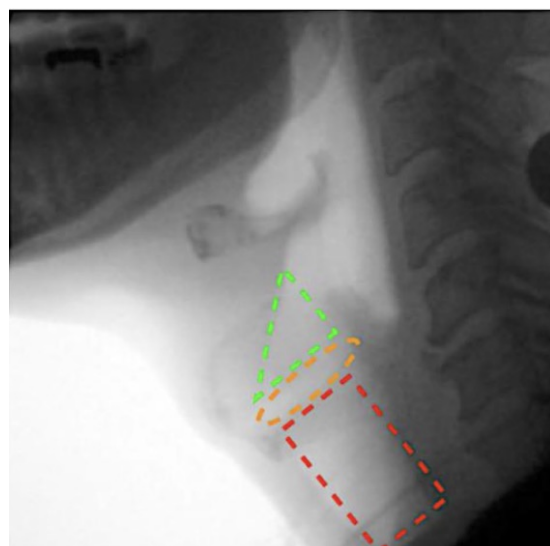
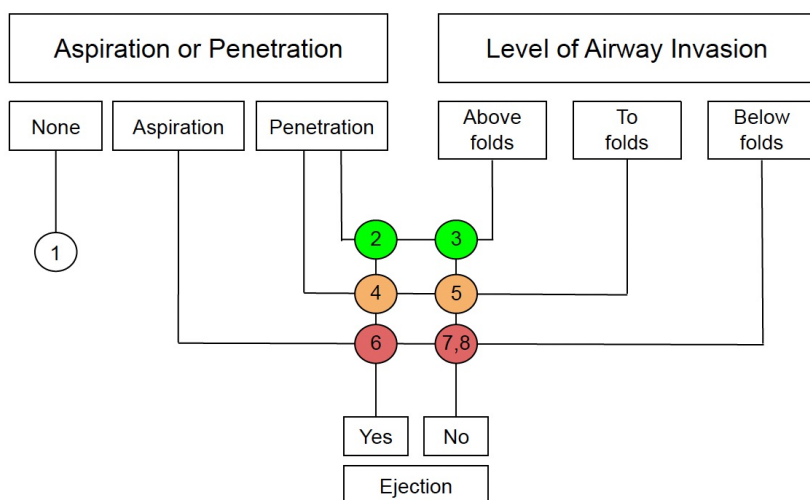
Name: _____ Date of birth: _____

The following shows the Penetration-Aspiration Scale (PAS) which is used in accordance with a videofluoroscopic swallow study to determine an individual's swallowing function. The scale uses an 8-point ordinal scale, with 1 representing the least and 8, the highest or most severe scores.

PA Scale score	Description
1	No contrast enters the airway
2	Contrast enters the airway, remains above the vocal folds, and is ejected from the airway (not seen in the airways at the end of the swallow)
3	Contrast enters the airway, remains above the vocal folds, and is ejected from the airway.
4	Contrast enters the airway, contacts the vocal folds, and is ejected from the airway.
5	Contrast enters the airway, contacts the vocal folds, and is not ejected from the airway.
6	Contrast enters the airway, crosses the plane of the vocal folds, and is ejected from the airway.
7	Contrast enters the airway, crosses the plane of the vocal folds, and is not ejected from the airway despite effort.
8	Contrast enters the airway, crosses the plane of the vocal folds, is not ejected from the airway and there is no response to aspiration.

Score:

The following diagram can be used to assist in determining which score is related to the patient (Alkhuwaiter et al., 2022).



References

Alkhuwaiter, M., Davidson, K., Hopkins-Rossabi, T., & Martin-Harris, B. (2022). Scoring the Penetration-Aspiration Scale (PAS) in Two Conditions: A Reliability Study. *Dysphagia*, 37(2), 407–416. <https://doi.org/10.1007/s00455-021-10292-6>

Coyle, J. L. (2017). Scaling the swallow. *The ASHA Leader*, 22(5), 36–38. <https://doi.org/10.1044/leader.otp.22052017.36>

Schmid, J. (n.d.). Penetration-aspiration scale | Radiology Reference Article | [Radiopaedia.org](https://radiopaedia.org). Radiopaedia. Retrieved November 21, 2024, from <https://radiopaedia.org/articles/penetration-aspiration-scale-2?lang=us>