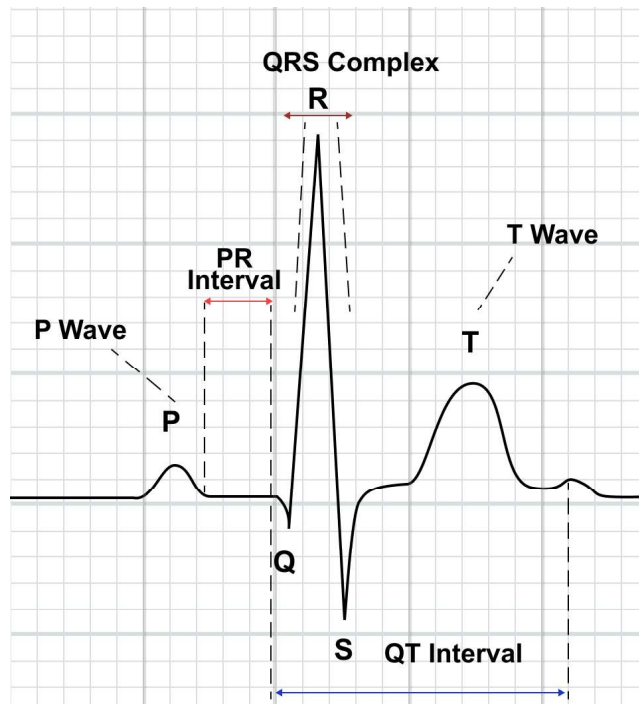


Normal ECG Values Chart

Name: Jason Taylor		Sex: Female
Age: 35	Date: August 20, 2024	
Diagnosis:		
Bradycardia		
Medical history:		
History of fatigue and dizziness, previous diagnosis of hypertension, currently on beta-blockers, family history of heart disease.		

ECG component	Normal range
Heart rate (HR)	60 - 100 beats per minute
P wave duration	0.06 - 0.12 seconds
PR interval	0.12 - 0.22 seconds
QRS complex duration	≤ 0.12 seconds
QT interval	0.36-0.44 seconds
QTc interval (corrected QT)	0.36-0.44 seconds or Males: ≤ 450 milliseconds Females: ≤ 470 milliseconds
T wave deflection	At least 5 of the 6 limb leads
T wave duration	0.1-0.25 seconds



Additional notes

The patient presents with bradycardia, likely exacerbated by beta-blocker use. The QTc interval is borderline high, which should be monitored closely due to the risk of QT prolongation. Adjusting medication dosage or alternative treatment options may be considered in the follow-up consultation.

References

ECG & ECHO Learning. (2017, May 30). *ECG interpretation: Characteristics of the normal ECG (P-wave, QRS complex, ST segment, T-wave)*. <https://ecgwaves.com/topic/ecg-normal-p-wave-qrs-complex-st-segment-t-wave-j-point/>

Rosenthal, L. (2024, February 16). *Normal Electrocardiography (ECG) Intervals: Normal Electrocardiography Intervals*. EMedicine. <https://emedicine.medscape.com/article/2172196-overview?form=fpf>

Sharma, R. (2024, March 26). *Normal ECG values chart explained*. Sunfox. <https://sunfox.in/blogs/normal-ecg-values-chart-explained/>