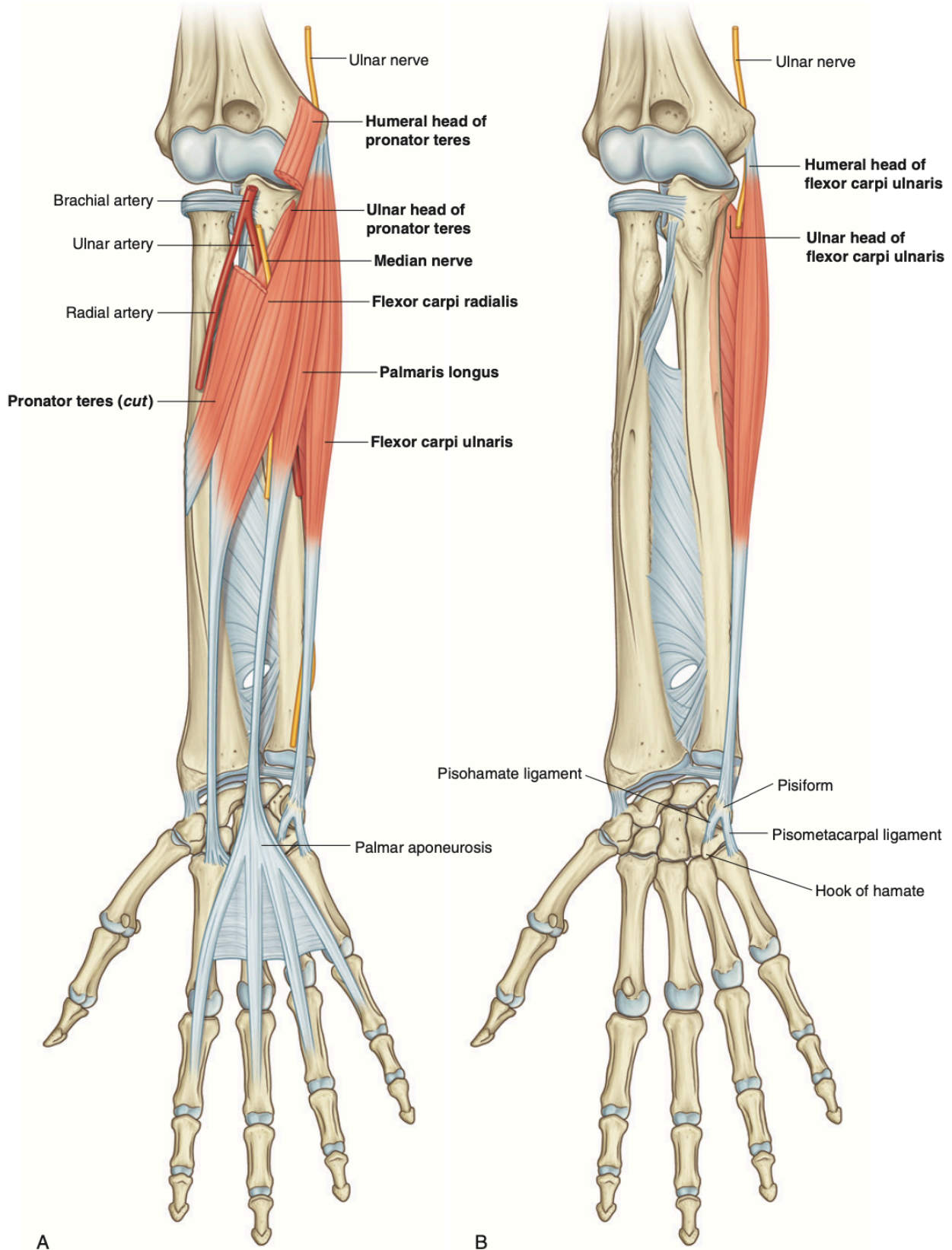


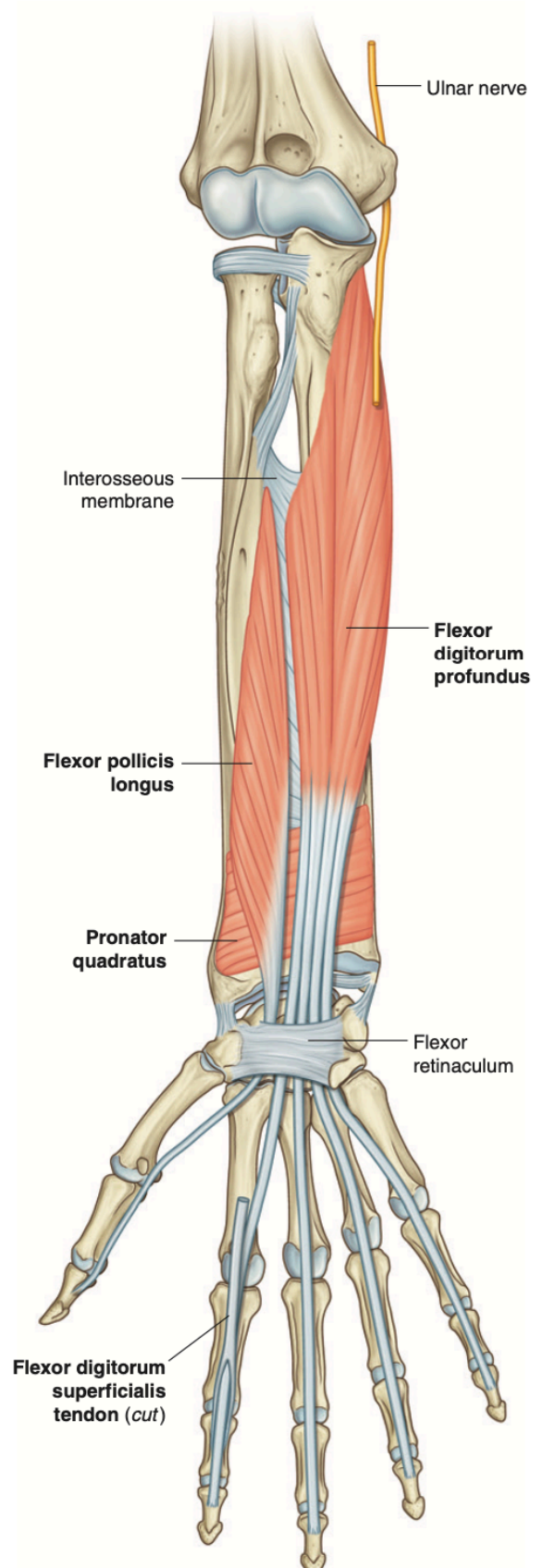
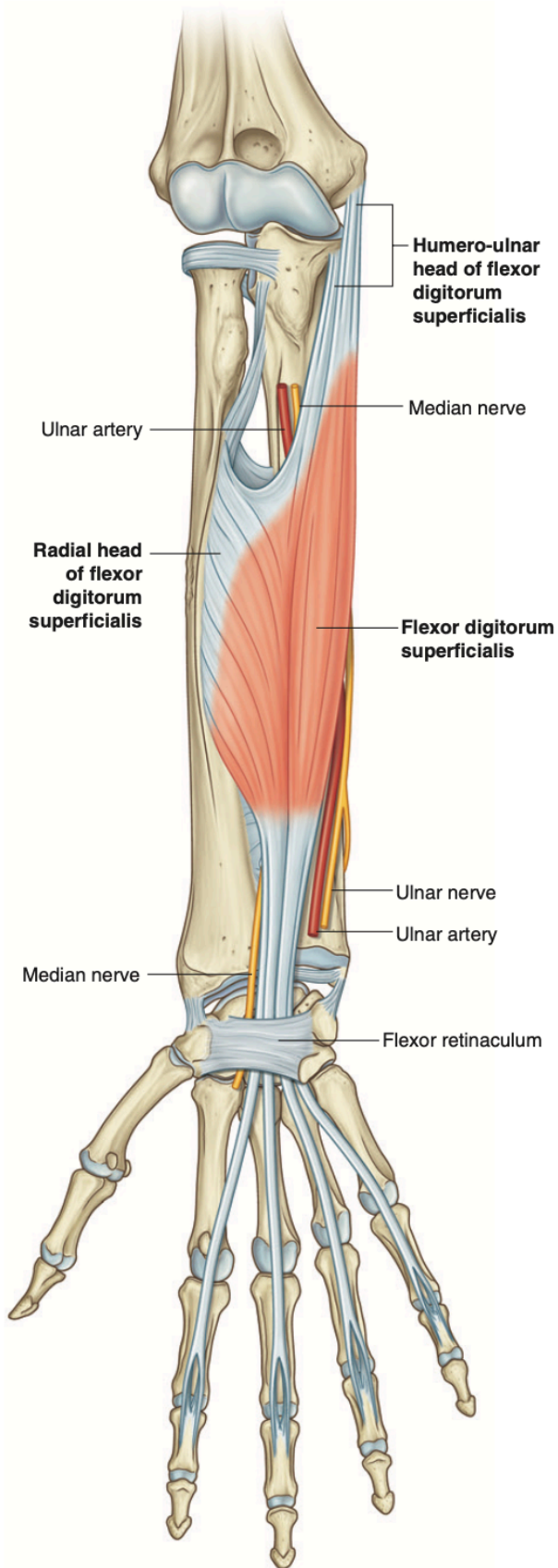
Forearm Muscle Diagram Template

Anterior Compartment

Superficial Layer

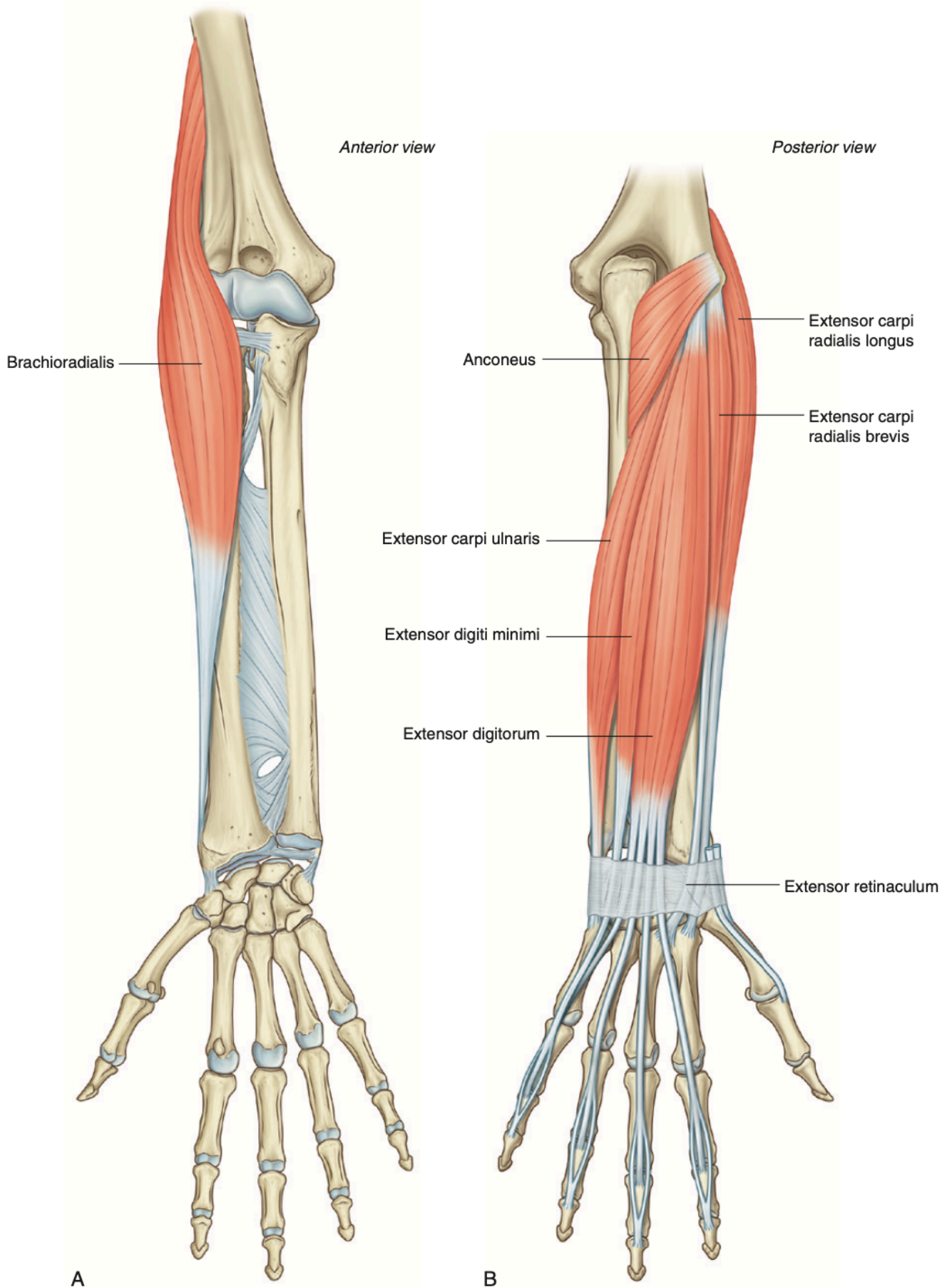


Intermediate and Deep Layer

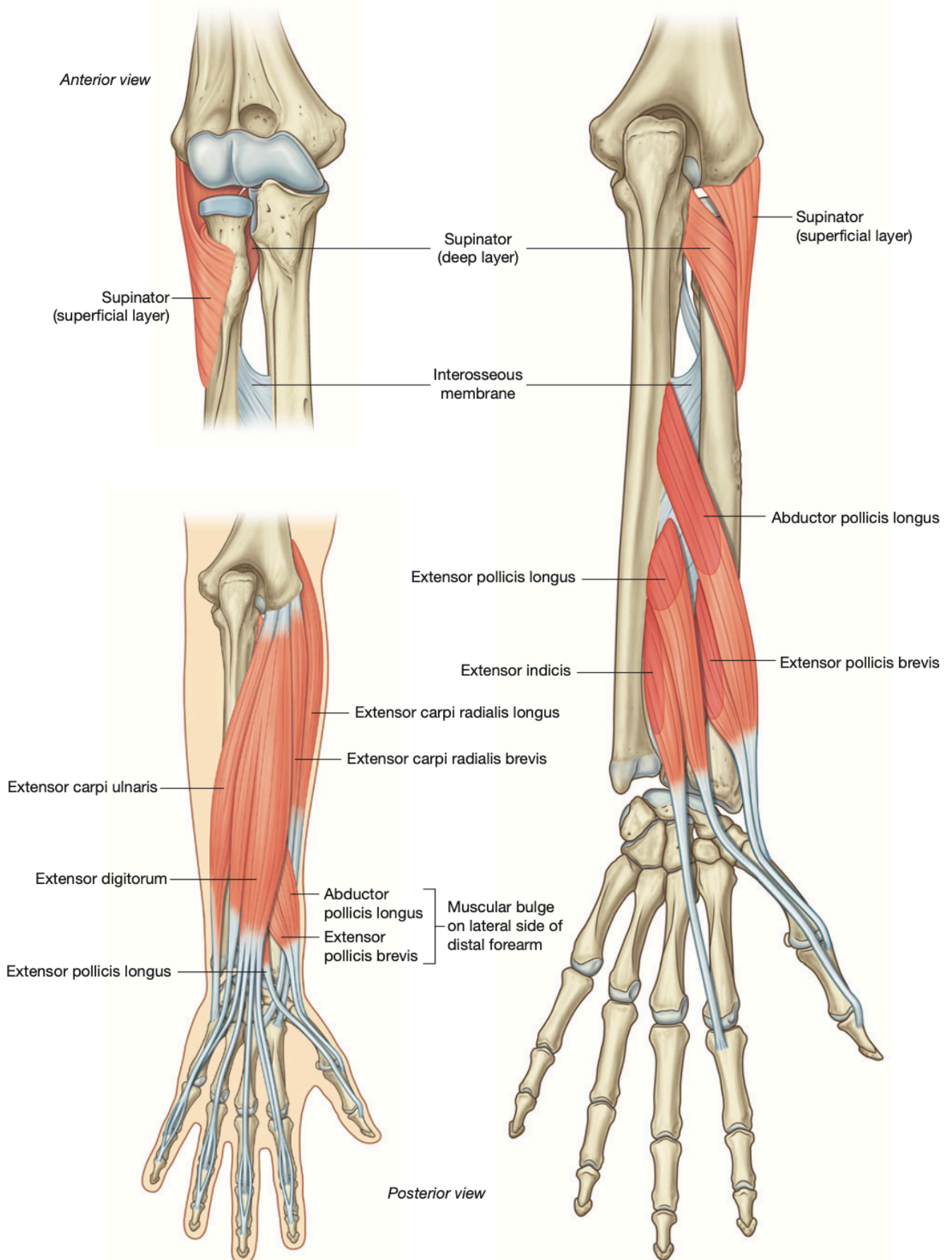


Posterior Compartment

Superficial Layer



Deep Layer



Additional Note: