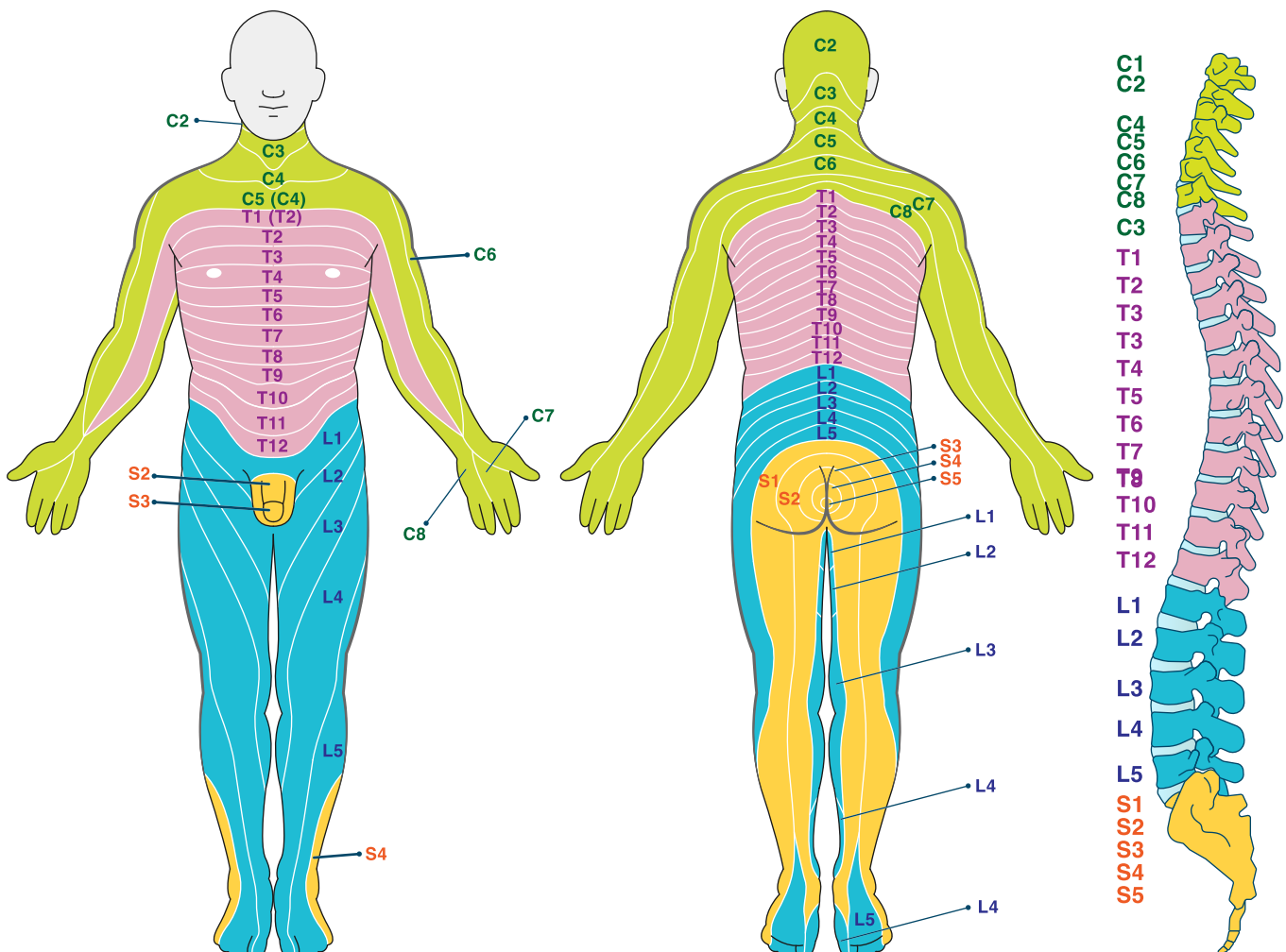
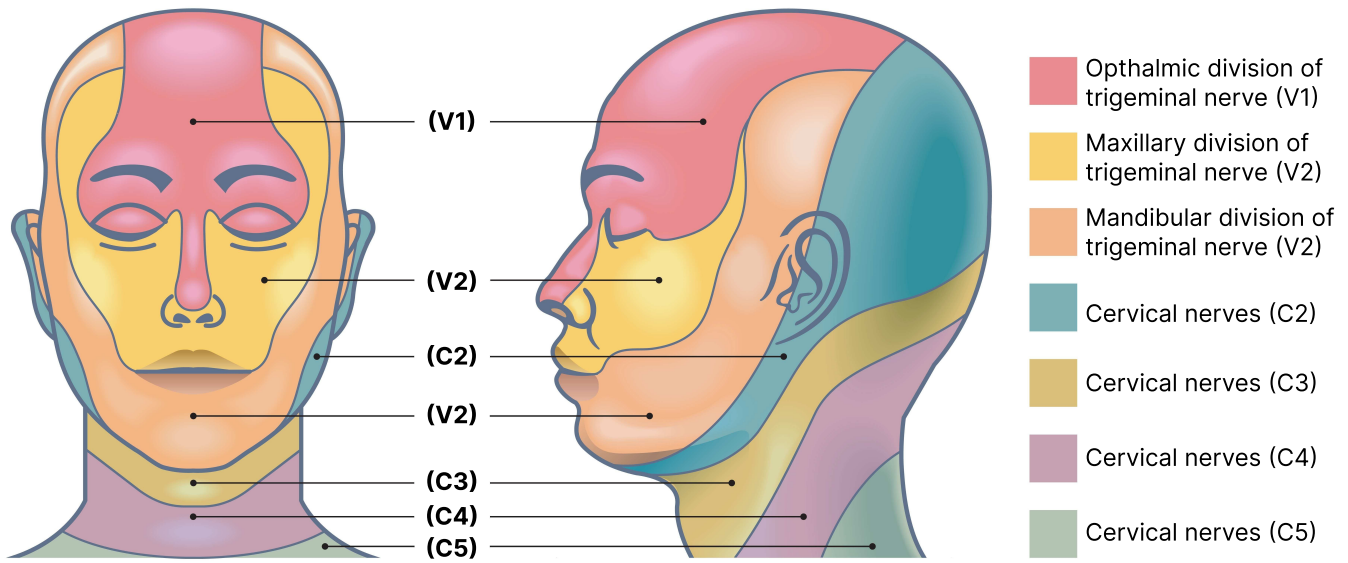


Dermatome Map



Cervical	Thoracic
<p>C2: lower jaw, back of the head</p> <p>C3: upper neck, back of the head</p> <p>C4: lower neck, upper shoulders</p> <p>C5: area of the collarbones, upper shoulders</p> <p>C6: shoulders, outside of arm, thumb</p> <p>C7: upper back, back of arm, pointer & middle finger</p> <p>C8: upper back, inside of arm, ring & little finger</p>	<p>T1: upper chest and back, armpit, front of arm</p> <p>T2: upper chest & back</p> <p>T3: upper chest & back</p> <p>T4: upper chest (area of nipples) & back</p> <p>T5: mid chest and back</p> <p>T6: mid chest and back</p> <p>T7: mid chest and back</p> <p>T8: upper abdomen & back</p> <p>T9: upper abdomen & back</p> <p>T10: abdomen (area of belly button) & mid back</p> <p>T11: abdomen & mid back</p> <p>T12: lower abdomen & mid back</p>
Lumbar	Sacral
<p>L1: lower back, hips, groin</p> <p>L2: lower back, front and inside of thigh</p> <p>L3: lower back, front and inside of thigh</p> <p>L4: lower back, front of high and calf, area of knee, inside of ankle</p> <p>L5: lower back, front & outside of calf, top & bottom of foot, first four toes</p>	<p>S1: lower back, back of thigh, back & inside of calf, last toe</p> <p>S2: buttocks, genitals, back of thigh & calf</p> <p>S3: buttocks, genitals</p> <p>S4: buttocks</p> <p>S5: buttocks</p>
Additional notes	

DeSai, C., Reddy, V., & Agarwal, A. (2023). Anatomy, back, vertebral column. In *StatPearls [Internet]*. StatPearls Publishing. <https://www.ncbi.nlm.nih.gov/books/NBK525969/>

Whitman, P. A., & Adigun, O. O. (2018). Anatomy, skin, dermatomes. In *StatPearls [Internet]*. Statpearls Publishing. <https://www.ncbi.nlm.nih.gov/books/NBK535401/>